

Incarcerated Amyand's hernia in a 6-week old infant repaired under spinal anesthesia

Toni Risteski ¹ Aleksandar Stepanovski ¹ Marjana Burmuzoska ²
Andrijana Andreevska Stepanovska ³ Jasminka Nancheva ²

¹University Clinic of Pediatric Surgery, Ss. Cyril and Methodius University of Skopje Medical Faculty, Skopje, North Macedonia.

²University Clinic of Anesthesiology, Reanimation and Intensive Care Unit, Ss. Cyril and Methodius University of Skopje Medical Faculty, Skopje, North Macedonia.

³University Clinic of Children's Diseases, Ss. Cyril and Methodius University of Skopje Medical Faculty, Skopje, North Macedonia.



Correspondence:

Aleksandar Stepanovski, MD
Resident in Pediatric Surgery
University Clinic of Pediatric
Surgery Skopje.

Address: Majka Tereza 17, 1000
Skopje, North Macedonia.

e-mail:

stepanovski.a@gmail.com

Specialty section:

This article was submitted to
Pediatric Surgery section

Received: 6 October 2022

Revised: 5 November 2022

Accepted: 9 November 2022

Published: 14 December 2022

Published by The JCTEI.



Abstract

Amyand's hernia is characterized by the presence of the vermiform appendix in an inguinal hernia sac. It occurs in less than 1% of all inguinal hernias in children's age. As the usual pediatric inguinal hernia, it can present in multiple ways, from uncomplicated to incarcerated and/or strangulated hernia with normal, inflamed or even perforated vermiform appendix within the hernia sac. The repair of all the infant cases we came across in literature involved herniorrhaphy with or without appendectomy and general anesthesia.

Herein, we present a case of Amyand's hernia in an infant with concomitant patent ductus arteriosus (PDA), patent foramen ovale (PFO) and interventricular septum hypertrophy that presented with signs and symptoms suggestive of ordinary right-sided incarcerated inguinoscrotal hernia. Due to the cardiac anomaly the infant underwent spinal anesthesia for the hernia repair, thus contributing to the rarity of the case. By thorough literature review, we could not find any similar case of Amyand's hernia incarceration in an infant operated on under spinal anesthesia. Furthermore, we discuss the surgical and anesthetic aspects of this condition in children.

Keywords: Amyand's hernia, infant, spinal anesthesia.

Introduction

Amyand's hernia (AH) denotes the presence of the vermiform appendix in an inguinal hernia sac. It occurs in approximately 1% of all inguinal hernias in pediatric age. The clinical manifestations of AH include uncomplicated, incarcerated and/or strangulated hernia. The vermiform appendix within the hernia sac can be uninflamed or at different stages of inflammation up to gangrene and perforation (1,2). The surgical management of AH consists of open or, more rarely, laparoscopic herniorrhaphy with or without concurrent appendectomy. General anesthesia was the preferred method for all the infant cases we found in the literature (3–8).

Case description

A 6-week-old full-term male infant was brought to our emergency department due to a right-sided inguinoscrotal swelling. The infant was crying and irritable with local inguinal tenderness, and a soft abdomen on palpation. Attempts at manual reduction were unsuccessful. A systolic murmur of 2/6 grade was audible on auscultation.

The previous history was notable for repeating episodes of cyanosis attributed to the patent ductus arteriosus (PDA) diagnosed by echocardiography. Additional heart findings included a patent foramen ovale (PFO) and hypertrophied interventricular septum. Apart from light dysmorphic features, no other congenital anomalies were noted. The anesthesiologist opted for spinal anesthesia (SA), as cardiac comorbidity precluded the usage of general anesthetics.

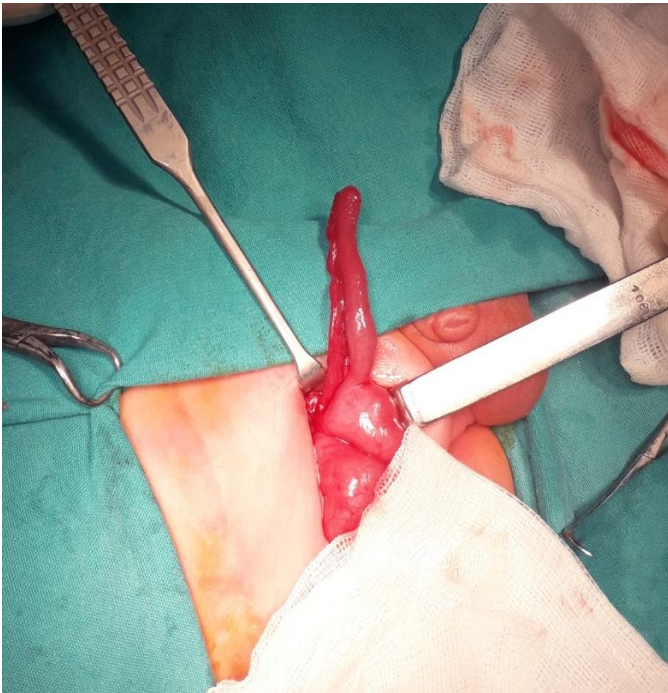


Figure 1: Intraoperative finding of a normal-looking vermiform appendix.

After routine intravenous line placement, the infant was positioned in a lateral decubitus position with slight neck flexion. Effective procedural sedation was achieved by administering 0.1-0.15 mg midazolam and 2-3 mg ketamine combination in three repeated bolus injections for the duration of operative procedure. The technique involved injecting 3.5 mg of isobaric 0.5% bupivacaine in the L4/L5 intrathecal space by using 26-gauge Atraucan needle.

The operative approach involved inguinal skin crease incision with subsequent opening of the inguinal canal. The hernia sac was meticulously dissected from the spermatic cord and by opening it, a vermiform appendix of 4 cm length and 0.6 cm width contiguous with part of the cecum was found (Figure 1). Given the size and the engorged appendiceal surface, probably from previous efforts at manual reduction, we opted for appendectomy with subsequent reduction of the cecum in the peritoneal cavity. Classical Ferguson and Gross hernia repair was performed, followed by scrotal fixation of the testicle in a Dartos pouch. Apart from one episode of cyanosis with a fall in oxygen saturation (SpO₂) to 65%, which was corrected by prompt oxygen supplementation, no other events were noted. The remainder of postoperative treatment was uneventful, and the child was transferred to the cardiac surgery colleagues for further treatment. Histology revealed marked lymphatic follicles in the lamina propria and congested blood vessels with signs of edema and moderate mononuclear inflammatory infiltrate in the subserosal layer.

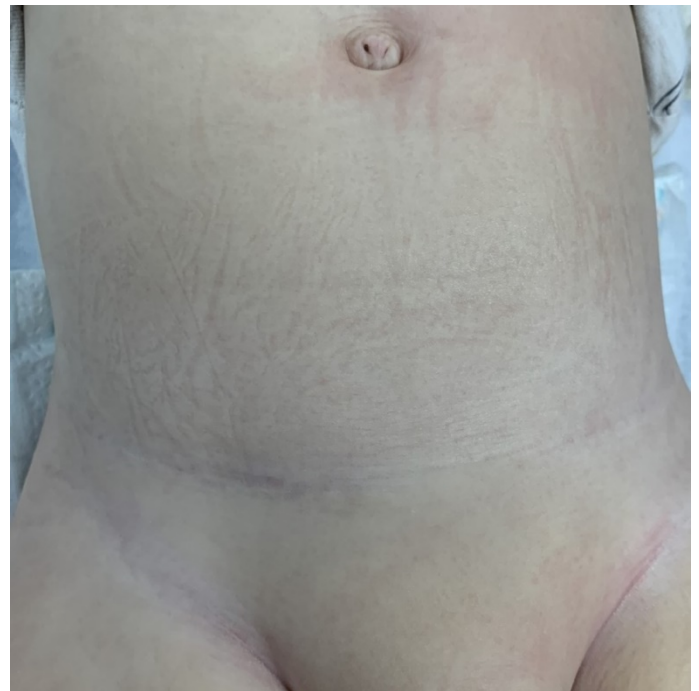

Figure 2: Local appearance at one-year follow-up. Satisfactory esthetic outcome as the incision followed the right groin skin crease.

The child was doing well at the one-year follow-up with satisfactory esthetic results, and no signs of hernia recurrence (Figure 2).

Discussion

The presence of the vermiform appendix, either normal or pathologically changed, in an inguinal hernia sac is termed Amyand's hernia. This eponymous condition is named after Claudius Amyand, a French surgeon who performed the first successful appendectomy in history by removing an acutely inflamed appendix in an inguinoscrotal hernia of an 11-year-old male in the 18th century (1,9).

It occurs more often in males and on the right side, for reasons that most of the inguinal hernias occur on the right side and the natural position of the vermiform appendix in the right lower abdominal quadrant. Rarely is AH left-sided and is usually associated with mobile cecum, situs inversus or intestinal malrotation (2-7).

The prevalence of AH ranges from 0.5 to 1%, being three times more common in children than in adults, due to the patency of the processus vaginalis (3, 9-14). On the other hand, only 0.1% of all cases of appendicitis present within a hernia sac (9,15-17).

On clinical examination, Amyand's hernia is usually mistaken for incarcerated or strangulated inguinal hernia. Other differential diagnoses include inguinal lymphadenopathy, hydrocele of the spermatic cord, epididymo-orchitis and testicular torsion (3,8,18-19).

Congenital bands from the appendix to the scrotum and the funnel-like neonatal cecum are often mentioned as predisposing factors for AH and potential incarceration (8). Some nutritional habits have been described to precipitate incarceration as well (10). Incarceration is further thought to stimulate appendicitis by means of reduced blood flow and traumatic events with subsequent inflammation and bacteria overgrowth (3,5). A case of secondary inflammation of the vermiform appendix in the sac has also been reported (3). Although traumatic manipulation of the appendix has been suggested to predispose to inflammation, this correlation lacks solid scientific grounds (1).

As the clinical signs and symptoms are non-specific for Amyand's hernia, the diagnosis is usually reached intraoperatively. Few reports point to a successful preoperative diagnosis with the utility of imaging studies. Ultrasonography can identify a tubular or appendix-like structure, and thus point to Amyand's hernia in a broader

differential sense (3,12,15). Despite being a useful diagnostic tool in a few cases of elderly patients, CT scan is not routinely included in the preoperative work-up, and the benefits in infants should be weighed against the hazards of radiation (5,13,14).

Nevertheless, we believe that it is appropriate to proceed to surgery in case of irreducible inguinal bulge only on clinical grounds, as imaging is not always readily available in emergency setting and most of the differential diagnoses at this site are surgical emergencies, as shown in our case.

The essence of treatment involves appendectomy with subsequent hernia repair. However, there is still an ongoing debate as to whether to remove an uninflamed appendix, with a substantial number of authors opting for a mere appendiceal reduction in the abdominal cavity. The presence of appendiceal lymphoid tissue, postoperative wound infection rate and the potential usage for reconstructive procedures are the usually cited reasons behind this approach (2,4,12).

One should note that macroscopic evaluation of the appendix is often subjective and not always correct (1). Our appendix showed some serosal redness and light edema probably as a result of the manual reduction maneuvers. Given the lifetime risk of 7% for appendicitis and the associated morbidity related to laparotomy/laparoscopy and complicated appendicitis, we decided to proceed with appendectomy.

Losanoff and Basson further advocated the concept of incidental appendectomy in younger patients with normal appendices, as the likelihood for appendicitis throughout life is highest in this age group. These authors are also credited with devising a four-type classification for AH based on the inflammation status of the vermiform appendix in a hernia sac (10).

In addition to the classical open inguinoscrotal hernia repair, there is an increasing number of reports of laparoscopic Amyand's hernia repair (5,11). The first intracorporeal laparoscopic appendectomy with bilateral hernia repair was performed by Rehman et al., while Li et al. described six cases of laparoscopic-assisted hernia repair with extracorporeal appendectomy (5,11). As this type of hernia manifests itself in different clinical fashion, from clear to vague signs of hernia, it is hard to standardize the surgical method. Laparoscopy would be a more suitable method

in cases of unclear complaints of abdominal pain, where exploration of the abdominal cavity tends to be more beneficial to the patient (16). Moreover, laparoscopy would be a questionable solution in cases of clearly palpable inguinal mass, where exploration of the inguinal canal is obligatory (16). Furthermore, laparoscopy is technically more demanding in infants in the setting of spinal anesthesia, and is not routinely employed (17).

All of the infant cases of Amyand's hernia we came across in literature, both elective and emergent, underwent general anesthesia (3–8). In our case, the unexpected combination of hernia incarceration and concomitant PDA and PFO constituted a relative contraindication to general anesthetics and therefore, spinal anesthesia seemed a reasonable alternative.

Spinal anesthesia has gained popularity in high-risk infants due to its safer profile regarding postoperative apnea and hypoxemia as compared to general anesthesia. It is generally considered to induce minimal respiratory or hemodynamic changes, although the effects on hemodynamics are still debated (18,19).

Shenkman et al. reported no postoperative apnea, oxygen desaturation, or bradycardia in his series of 44 infants with congenital heart diseases undergoing inguinal hernia repair under SA (18).

Ceccanti et al. in his large single-center study of 68 and 37 premature infants undergoing inguinal hernia repair under spinal and general anesthetic, respectively, did not report any adverse effects of SA such as hypotension, bradycardia or respiratory failure compared to general anesthesia (20). The study also suggested that weight less than 4000 g and operative procedures lasting less than 40 minutes were important predictors for successful outcomes in SA. Interestingly, among the four converted cases to general anesthesia in this series, due to prolonged operative times, there was an infant with Amyand's hernia adherent to the hernia sac (20).

The perioperative period in our case went uneventful, and the cyanotic crisis afterwards was attributed to the congenital heart anomaly. The motor and sensory blockade proved effective and without interference to vital signs. No adverse effects from the anesthetic were reported.

Overall, our experience with spinal anesthesia was good and should be taken into account in similar clinical circumstances.

Conclusions

Incarcerated Amyand's hernia is a rare entity in infants. The hernia should be promptly repaired, with the choice to either leave or resect a normal appendix being at the surgeon's discretion. Spinal anesthesia could be a safe and effective alternative to general anesthesia in an emergency setting.

Conflict of interest:

The authors report no conflict of interest.

Funding source:

No funding was required.

Ethical approval:

Ethical approval was obtained from the Haydarpaşa Training Hospital in 09/2010.

Contributions

Research concept and design: **TR, AS, MB, AAS, JN**
Data analysis and interpretation: **TR, AS, MB, AAS, JN**
Collection and/or assembly of data: **TR, AS, MB, AAS, JN**
Writing the article: **TR, AS, MB, AAS, JN**
Critical revision of the article: **TR, AS, MB, AAS, JN**
Final approval of the article: **TR, AS, MB, AAS, JN**

Acknowledgments

No

References

1. Cankorkmaz L, Ozer H, Guney C, Atalar MH, Arslan MS, Koyluoglu G. Amyand's hernia in the children: a single center experience. *Surgery*. 2010;147(1):140-3.
2. Cigsar EB, Karadag CA, Dokucu AI. Amyand's hernia: 11 years of experience. *J Pediatr Surg*. 2016;51(8):1327-9.
3. Park J, Hemani M, Milla SS, Rivera R, Nadler E, Alukal JP. Incarcerated Amyand's hernia in a premature infant associated with circumcision: a case report and literature review. *Hernia*. 2010;14(6):639-42.
4. Baldassarre E, Centonze A, Mazzei A, Rubino R. Amyand's hernia in premature twins. *Hernia*. 2009;13(2):229-30.
5. Li B, Zhang JY, Wang YB, Chen WB, Wang SQ, Jin LG, et al. Laparoscope-assisted diagnosis and treatment for Amyand's hernia in children-report of six cases. *Pediatr Surg Int*. 2013;29(5):525-8.

6. Murugan S, Grenn EE, Morris MW Jr. Left-Sided Amyand Hernia. *Am Surg.* 2022;88(7):1561-2.
7. Khan RA, Wahab S, Ghani I. Left-sided strangulated Amyand's hernia presenting as testicular torsion in an infant. *Hernia.* 2011;15(1):83-4.
8. Milburn JA, Youngson GG. Amyand's hernia presenting as neonatal testicular ischaemia. *PediatrSurg Int.* 2006;22(4):390-2.
9. Losanoff JE, Basson MD. Amyand hernia: what lies beneath--a proposed classification scheme to determine management. *Am Surg.* 2007;73(12):1288-90.
10. Supangat, Pratama HA, Sejati NES, Romadhon BD, Sulistyani I. Left-side incarcerated Amyand's hernia with appendix and caecum provoke by early banana diet: a case report. *BMC Gastroenterol.* 2021;21(1):165.
11. Rehman MR, Panteli C, Tsang T. Laparoscopic repair of Amyand's hernia in an 8-week-old infant. *Hernia.* 2010;14(4):443-5.
12. Naumeri F, Ahmad HM, Bin Zia Khan MT. Amyand's hernia in an eighteen month old boy: A case report. *J Pak Med Assoc.* 2018;68(10):1525-6.
13. Luchs JS, Halpern D, Katz DS. Amyand's hernia: prospective CT diagnosis. *J Comput Assist Tomogr.* 2000;24(6):884-6.
14. Ash L, Hatem S, Ramirez GA, Veniero J. Amyand's hernia: a case report of prospective ct diagnosis in the emergency department. *Emerg Radiol.* 2005;11(4):231-2.
15. Okur MH, Karaçay S, Uygun I, Topçu K, Öztürk H. Amyand's hernias in childhood (a report on 21 patients): a single-centre experience. *Pediatr Surg Int.* 2013;29(6):571-4.
16. Baldassarre E, Ferrero C, Da Costa Duarte D, Barone M, Prosperi Porta I. Amyand's hernia in infancy: why laparoscopy? *J Pediatr Surg.* 2009;44(8):1673-4.
17. Eizaga Rebolgar R, García Palacios MV, Morales Guerrero J, Torres Morera LM. Spinal Anesthesia for Pediatric Laparoscopic Hernia Repair: A Case Report. *A Pract.* 2018;11(11):293-5.
18. Shenkman Z, Johnson VM, Zurakowski D, Arnon S, Sethna NF. Hemodynamic changes during spinal anesthesia in premature infants with congenital heart disease undergoing inguinal hernia correction. *Paediatr Anaesth.* 2012;22(9):865-70.
19. Astuto M, Sapienza D, Di Benedetto V, Disma N. Spinal anesthesia for inguinal hernia repair in an infant with Williams syndrome: case report. *Paediatr Anaesth.* 2007;17(2):193-5.
20. Ceccanti S, Cervellone A, Pesce MV, Cozzi DA. Feasibility, safety and outcome of inguinal hernia repair under spinal versus general anesthesia in preterm and term infants. *J Pediatr Surg.* 2021;56(5):1057-61.