

Evaluation of endometrial polyps in terms of mast cells, estrogen and progesterone receptors, MMP-2, MMP-9, and COX-2 markers and distribution of endometrial polyps in menopausal/premenopausal breast cancer patients

Öznur Öner ¹ Levent Tütüncü ² Zafer Küçükodacı ³

¹Uşak University Faculty of Medicine, Department of Gynecology and Obstetrics, Uşak, Turkey.

²Okan University Faculty of Medicine, Department of Gynecology and Obstetrics, Istanbul, Turkey.

³Anadolu Medical Center Hospital, Department of Pathology, Turkey.



Correspondence:

Öner Ö, Uşak University Faculty of Medicine, Department of Gynecology and Obstetrics, Uşak, Turkey.

e-mail: oneroznur@hotmail.com

Specialty section:

This article was submitted to the Gynecology section

Received: 10 October 2022

Revised: 30 October 2022

Accepted: 1 November 2022

Published: 7 December 2022

Copyright© 2022 Published by The JCTEI.



Abstract

Objective: In this study, it was aimed to determine the expression of ER, PR, mast cell, MMP-2, MMP-9, and COX-2 in endometrial polyps, to evaluate whether they have a role in etiopathogenesis and to reveal whether the information obtained in this way can be used in treatment. Additionally, it aimed to show the distribution of these markers in endometrial polyps in menopausal and premenopausal breast cancer patients.

Materials and methods: In this study, 51 patients who were reported as having "endometrial polyp" as a result of pathological examination of endometrial curettage or hysteroscopic polyp extirpation materials in Gynecology and Obstetrics Service of Gülhane Military Medical Academy Haydarpaşa Training Hospital were evaluated retrospectively.

Results: While the rate of patients with moderate immunohistochemical staining of MMP-2 in postmenopausal patients (47.1%) was found to be significantly higher than the premenopausal group (11.8%), the rate of patients with weak immunohistochemical staining (47.1%) in premenopausal patients was compared to the postmenopausal group (14.7%) was found to be statistically significantly higher. The prevalence of immunohistochemical staining of MMP-9 in the group receiving HRT among postmenopausal patients was found to be statistically significantly higher than in those who did not receive HRT ($p=0.012$). The immunohistochemical staining intensity of MMP-9 in the group receiving HRT among postmenopausal patients was also found to be statistically significantly higher than those who did not receive HRT ($p=0.012$).

Conclusions: As a result, MMP-2, MMP-9, and mast cells may contribute to the endometrial polyp formation steps in postmenopausal patients. The possible contribution of MMP-2, MMP-9, and mast cells to the etiopathogenesis may resolve the contradictions in the formation mechanism of postmenopausal polyps. If this information is proven as a result of more comprehensive studies to be done later, it may be possible to prevent endometrial polyps and to create non-surgical treatment options, especially in the general postmenopausal patient group and in patients receiving HRT.

Keywords: Breast cancer, endometrial polyps, mast cells, MMP-2, COX-2.

Introduction

An endometrial polyp, or uterine polyp, is an abnormal growth involving glands, stroma, and blood vessels that protrude from the uterine lining (endometrium) that lines space small or large enough to fill the uterine cavity. They are found in both reproductive and postmenopausal stages of life (1). Most of the polyps are located in the fundus, often in the cornea region, and there are obvious technical difficulties in removing them by curettage (2). They range from about 5 mm to wide enough to fill the entire uterine cavity (3), can be found in all age groups, but are most common between the ages of 40 and 49 (4). Endometrial polyps are common, focal, usually benign lesions in the endometrium. While its prevalence is 8% in the general population, this rate varies between 13-50% in patients with abnormal uterine bleeding (5,6).

There are two isoforms of estrogen receptors (ER), alpha (ER- α) and beta (ER- β). While ER- α is mostly found in the uterus, breast, testis, pituitary, liver, kidney, heart, and skeletal muscle, ER- β is found especially in the ovary and prostate (7-9). The estrogenic effect in the endometrium takes place, especially through ER- α . Progesterone receptors (PR) also have 2 isoforms: PR-A and PR-B. They mediate the action of progesterone during menstruation. Studies give clues that abnormal expression of hormone receptors may play a role in polyp formation. In addition, it is known that endometrial polyps are more common in patients receiving hormone replacement therapy or given tamoxifen for breast cancer (10-12). In light of these findings, it is aimed to clarify their roles in etiopathogenesis by showing the distribution of estrogen and progesterone receptors in endometrial polyps.

Mast cells are thought to play a role in menstruation. There are 3 subtypes of these cells: those containing tryptase, those containing chymase, and those containing tryptase and chymase. It is stated that the number of mast cells expressing tryptase is seven times higher in endometrial polyps than in the normal endometrium. It is considered that this finding may be related to the formation of polyps in various tissues, especially in the endometrium (13).

Expression of matrix metalloproteinase (MMP) and cyclooxygenase (COX) is affected by estrogen levels. MMPs are involved in embryogenesis and tissue regeneration. It is also known to play a role in tumor

invasion and metastasis, loss of adhesion, and angiogenesis. COX-2 is thought to play a role in angiogenesis and decidualization in the endometrium. COX-2 is over-expressed in endometrial hyperplasia and endometrial cancer (14-16). However, the expression of MMP-2, MMP-9, and COX-2 in endometrial polyps has not been clearly elucidated.

In this study, it was aimed to determine the expression of ER, PR, mast cell, MMP-2, MMP-9, and COX-2 in endometrial polyps, to evaluate whether they have a role in etiopathogenesis and to reveal whether the obtained information can be used in treatment. It was aimed to show the distribution of these markers in endometrial polyps in both menopausal and premenopausal breast CA patients.

Materials and methods

This study was carried out in the Gynecology and Obstetrics Service of Gülhane Military Medical Academy Haydarpaşa Training Hospital between January 2007 and December 2008. Informed consent was obtained from each patient before hysteroscopy and curettage. Ethical approval was obtained from the Haydarpaşa Training Hospital in 09/2010.

Patients

A total of 51 patients who were reported as having "endometrial polyp" as a result of pathological examination of endometrial curettage or hysteroscopic polyp extirpation materials were evaluated retrospectively.

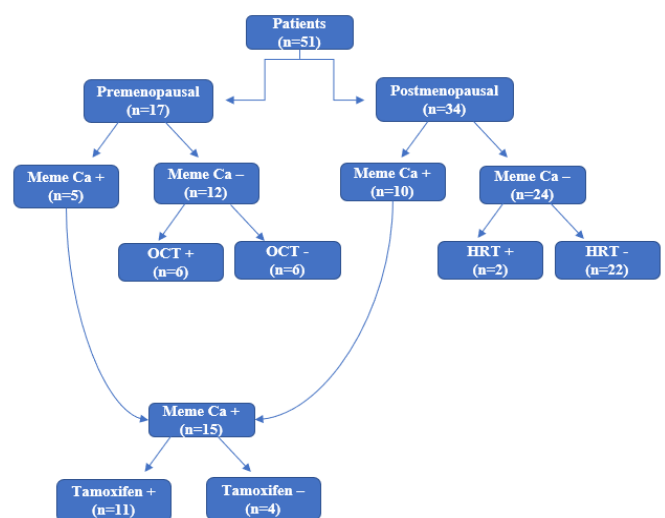


Figure 1: Patients (OCT: Oral Contraceptive Treatment; HRT: Hormone Replacement Therapy)

None of the patients had a history of NSAID use. All patients included in the study were in the same period of the menstrual cycle, all in the proliferative phase during these procedures. Evaluation of polyps was made in the formalin-fixed paraffin-embedded archive material of the patients. The patients were divided into two main groups premenopausal and postmenopausal according to their menopausal status.

There were 17 patients in the premenopausal group and 34 patients in the postmenopausal group. Each group was divided into those with and without breast CA. Of the 15 patients with breast CA, 10 were in the postmenopausal group and 5 were in the premenopausal group. These patients were divided into 2 groups according to whether they took tamoxifen or not. The number of patients using tamoxifen was 11, and the number of patients not using it was 4. Twenty-four postmenopausal patients without breast CA were divided into two groups according to whether they received hormone replacement therapy or not, and 12 premenopausal patients were divided into two groups according to whether they received oral contraceptives (OCT) or any other way of hormone therapy (HRT) (Figure 1).

Polyp materials of each patient were evaluated separately for estrogen receptor (ER), progesterone receptor (PR), cyclooxygenase-2 (COX-2), mast cell tryptase, matrix metalloproteinase (MMP)-2, and MMP-9.

Immunohistochemistry

The blocks that were prepared by fixing with 10% formalin and paraffinized were determined to be suitable for the study. In order to immunohistochemically evaluate ER, PR, mast cell tryptase, MMP-2, MMP-9, COX-2 antibodies from these blocks, 5 μ m thick sections were taken on positively charged slides. Sections were incubated at 55°C for 17 hours and after standard deparaffinization and rehydration procedures were performed, ER (Leica-Novocastra Lyophilized Mouse Monoclonal Antibody - Estrogen Receptor: NCL-ER-6F11), PR (Leica-Novocastra Lyophilized Mouse Monoclonal Antibody - Progesterone Receptor: NCL-PGR-312), mast cell tryptase (Leica-Novocastra Lyophilized Mouse Monoclonal Antibody - Mast Cell Tryptase:NCL-MCTryp-428), MMP-2 (Leica-Novocastra Lyophilized Mouse Monoclonal Antibody-Matrix Metalloproteinase 2:NCL-MMP2-507), MMP-9 (Leica-Novocastra Lyophilized Mouse Monoclonal

Antibody-Matrix Metalloproteinase 9:NCL-MMP9-439), COX-2 (Leica-Novocastra Lyophilized Mouse Monoclonal Antibody-Cyclooxygenase-2:NCL-COX-2) with primary antibodies Immunohistochemical staining was completed in accordance with recommended procedures.

Evaluation

Sections were evaluated under a Nikon E600 light microscope. Non-polyp endometrial areas were not included in the evaluation. When evaluating estrogen and progesterone receptor protein expression, only nuclear staining in glandular cells was taken into account, and nuclear staining in stromal cells was excluded. When evaluating the prevalence of staining; negative staining = 0, less than 1% positive staining = 1, 1-10% positivity = 2, 10-33% positivity = 3, 33-66% positivity = 4, more common positive than 66% staining was scored as 5 (7). Staining intensity was graded as a weak, medium, and strong.

The prevalence of cytoplasmic staining in glandular cells was taken into account when evaluating COX-2 expression. Staining in stromal cells was excluded. Less than 10% staining = 0 (negative), 10-25% positive staining = 1, 25-50% positive staining = 2, and more than 50% positive staining = 3.

In the evaluation of MMP-2 and MMP-9 expression, the prevalence and severity of cytoplasmic staining in glandular cells were taken into account. Positive staining between 0-25% was scored as 1, between 25-50% positive staining = 2, and positive staining over 50% was scored as 3. Staining intensity was also graded as a weak, medium, and strong.

For the evaluation of mast cell tryptase expression, 10 high magnification fields (BBA) were evaluated in the polyp area, positive cells were counted and averaged, and the number of mast cells per mm^2 was calculated. This calculation was performed using a fixed eyepiece (CFI 10X/22) and objective (40X, Plan Fluor) in a Nikon E600 light microscope. BBA was calculated according to the formula πr^2 . In this formula, $\pi = 3.14$ is taken. The radius was calculated as $(r) = 0.275$ (Diameter = $22/40 = 0.55$). According to the area formula above, $\text{BBA} = 0.237 \text{ mm}^2$. When calculating the number of mast cells per mm^2 , the number of mast cells in each BBA was multiplied by $1/0.237 = 4.2$.

Statistical analysis

While evaluating the findings obtained in the study, the statistics package program (SPSS 17) was used for statistical analysis. While evaluating the study data, the Pearson Chi-Square test was used to compare qualitative data as well as descriptive statistical methods (frequency, percentage, mean, standard deviation). The Kolmogorov-Smirnov distribution test was used to examine the normal distribution.

The Mann-Whitney U test was used to compare the quantitative data since the parameters that did not set normal distribution were compared between paired groups. Results were evaluated bilaterally at a 95% confidence interval (CI), a significance level of $p < 0.05$.

Results

The mean age of the cases was calculated as 58.29 ± 12.94 (33-80) years. The patients were divided into two main groups premenopausal and postmenopausal according to their menopausal status. The mean age of the premenopausal patients was 43.77 ± 5.25 (33-51) years. There were 17 patients in this group with a mean age of 12.11 years at menarche and a mean number of deliveries of 2.3. The mean body mass index (BMI) of the patients was 23.5 kg/m^2 . The first complaint of admission to the outpatient clinic was metrorrhagia in 6 patients, menorrhagia in 5 patients, spotting in 3 patients, and infertility in 2 patients. In 1 patient, the diagnosis was made incidentally during a routine gynecological examination. The mean age of the patients in the postmenopausal group was 65.56 ± 8.79 (52-80) years. In this group, there were 34 patients with a mean age of 12.14 years at menarche, an average age of 50.14 years at menopause, and a mean number of births of 2.47. The mean BMI of the patients was 24.1 kg/m^2 . Seventeen patients were asymptomatic and diagnosed incidentally during the routine gynecological examination; 14 patients were admitted to the outpatient clinic with complaints of postmenopausal bleeding (PMB), 2 patients with vaginal discharge, and 1 patient with groin pain (Table 1).

Each group was divided into those with or without breast CA. The mean age of patients with breast CA was 60.93 ± 12.65 (42-76) years, and the mean age of patients without breast CA was 57.19 ± 13.08 (33-80) years. The difference between the mean age of the patients in these two groups was not statistically significant ($p = 0.402$). In the breast CA group, there were 15 patients, 5

premenopausal and 10 postmenopausal, with a mean age of 12 years, a mean number of deliveries of 2.53, and a mean BMI of 23.9 kg/m^2 . Among these postmenopausal patients, the mean age of menopause was 49.8 years, and the diagnosis was made incidentally in 7 of them when an increase in endometrial echo was detected during routine gynecological examination, and 3 of them applied to the outpatient clinic with the complaint of postmenopausal bleeding. Of the premenopausal breast cancer patients, 2 had metrorrhagia, 2 had menorrhagia, and 1 was diagnosed incidentally during a routine gynecological examination.

Table 1: Evaluation according to menopausal status

	Premenopausal (n=17)	Postmenopausal (n=34)
Age (year)	43.77 ± 5.25	65.56 ± 8.79
Menarche age (mean)	12.11	12.14
Age at menopause	-	50.14
Number of parity (mean)	2.30	2.47
BMI (kg/m^2)	23.5	
<hr/>		
Complaints (n)		
Metrorrhagia	6	-
Menorrhagia	5	-
Spotting bleeding	3	-
Infertility	2	-
Incidentally	1	17
Post-menopausal bleeding	-	14
Vaginal discharge	-	2
Groin pain	-	1

In the patient group without breast cancer, there were a total of 36 patients, 12 of whom were premenopausal and 24 were postmenopausal, with a mean age of 12.19 years at menarche, a mean number of births of 2.52, and a mean BMI of 24.18 kg/m^2 . The mean age of menopause in postmenopausal patients was 50.1 years. Ten of the patients were asymptomatic. A total of 11 patients applied to the outpatient clinic with complaints of postmenopausal bleeding, 2 patients with vaginal discharge, and 1 patient with groin pain (Table 2). Patients with breast CA were divided into 2 groups according to whether they took tamoxifen or not. While there were 11 patients aged between 42-76 years in the

tamoxifen group, there were 4 patients aged between 42-70 years in the group that did not use tamoxifen. Postmenopausal patients without breast cancer were divided into two groups according to whether they took HRT or not, and premenopausal patients were divided into two groups according to whether they had received hormone therapy by OCT or any other means before. There were 2 patients with a mean age of 55 years in the postmenopausal patient group receiving HRT, and a total of 22 patients aged between 53-80 years in the group not receiving HRT. Among the premenopausal patients, there were 6 patients aged between 33-50 in the group that had used OCT before, and 6 patients aged between 37-51 in the group that did not use OCT. There was no significant difference between any of the groups in terms of epidemiological parameters ($p>0.05$).

Table 2: Evaluation according to breast cancer status

	Breast Ca + (n=15)	Breast Ca - (n=36)
Age	60.93±12.65	57.19±13.08
Menarche age (mean)	12.00	12.19
Age at menopause	49.8	50.1
Number of parity (mean)	2.53	2.52
BMI (kg/m ²)	23.9	24.18
Premenopausal (n)	5	12
Postmenopausal (n)	10	24
<hr/>		
Complaints (n)		
Metrorrhagia	2	-
Menorrhagia	2	-
Spotting bleeding	-	-
Infertility	-	-
Incidentally	8	10
Post-menopausal bleeding	3	11
Vaginal discharge	-	2
Groin pain	-	1
N/A	-	12

In postmenopausal patients, the rate of those with moderate immunohistochemical staining of MMP-2 (47.1%) was found to be significantly higher than in the premenopausal group (11.8%); the rate of thin patients (47.1%) in premenopausal patients was statistically significantly higher than in the postmenopausal group (14.7%) ($p=0.031$).

There was no statistically significant difference between the postmenopausal and premenopausal groups in terms

of ER, PR, COX-2, MMP-9 staining prevalence and severity, mast cell count, and MMP-2 staining prevalence ($p>0.05$). Additionally, there was no significant difference between the groups with and without breast CA in terms of factors ($p>0.05$). There was no significant difference between the groups using and not using tamoxifen in terms of factors ($p>0.05$).

The prevalence of immunohistochemical staining of MMP-9 in the group receiving HRT among postmenopausal patients was found to be statistically significantly higher than in those who did not receive HRT ($p=0.012$). The immunohistochemical staining intensity of MMP-9 in the group receiving HRT among postmenopausal patients was also found to be statistically significantly higher than those who did not receive HRT ($p=0.012$). In the comparisons made between the groups that received and did not receive HRT in postmenopausal patients, no significant difference was found in terms of other factors ($p>0.05$).

In the comparisons made between the groups using and not using OCT in premenopausal patients, no significant difference was found in terms of factors ($p>0.05$).

Discussion

Endometrial polyps are focal and usually benign lesions originating from the endometrium, mostly seen in the uterine fundus. Polyps, single or multiple, pedunculated or sessile in many appearances, are microscopically composed of endometrial epithelium overlying a fibrous stromal component. Since endometrial polyps are mostly asymptomatic, their prevalence is not known clearly, but it is expressed as approximately 8%, and this rate may increase up to 13-50% in patients with abnormal uterine bleeding (5,6). The frequency of polyps, which are very rare before the age of 20, increases with age and peaks in the 50s, and decreases again after menopause (14).

In our study, the mean age of the cases was found to be 58.29 ± 12.94 (33-80) years. This value was considered to be compatible with the literature.

The etiology of endometrial polyps has not yet been fully elucidated. As in the emergence of many endometrial disorders, the mitogenic effect of estrogen not met with progesterone has been blamed (17). However, the increase in the frequency of endometrial polyps in advancing age and the occurrence of endometrial polyps in the postmenopausal period contradict this view. In

another study, it is stated that abnormal expression of hormone receptors may play a role in polyp formation (7). It is not clear whether polyps in premenopausal and postmenopausal periods occur with the same mechanism (14). Therefore, in our study, endometrial polyps were evaluated separately in terms of ER, PR, COX-2, MMP-2, MMP-9, and mast cell tryptase expressions in these two groups, and it was tried to determine whether there was a difference between them.

In the reproductive period, growth and maturation occur in the ovarian follicles with the regulatory effect of steroid hormones, while cyclic changes occur in the endometrium such as proliferation, differentiation, and cell death. These steroid hormones produce their effects through the ER and PR. The ER and PR are members of the nuclear hormone receptor superfamily, which also includes androgen and retinoid receptors. These receptors are located in the cytosol of target cells and act as ligand-dependent transcription factors. In the study of Gül et al. (18), ER and PR expression in endometrial polyps in premenopausal and postmenopausal patients were evaluated, and no statistically significant results were found between the two groups in terms of glandular ER and PR expression. In the literature, conflicting results were found in studies comparing polyp tissue and adjacent normal endometrial tissue. In the study of Mittal et al. (19), no difference was found between the expression of glandular ER and PR in polyps and the expression in the normal endometrium. In the studies of Lopez et al. (20) and Sant'Ana et al. (21) it was observed that the expression of glandular ER and PR in the polyp was increased compared to the normal endometrium, and it was claimed that this increase caused the formation of polyps. In our study, the prevalence and severity of ER and PR staining in the preparations of the patients in both groups were compared in order to evaluate the premenopausal and postmenopausal patient groups in terms of ER and PR expression. As a result of this comparison, no significant difference was found between the two groups in terms of prevalence and severity of ER and PR staining, similar to Gül et al. (18). Based on this result, it was evaluated that the mechanisms of polyp formation between these two groups were not different in terms of ER and PR. However, in our study, while the expression of glandular ER and PR in the polyp tissue was evaluated, the adjacent normal endometrium tissue or the expression of stromal ER and PR were not evaluated, so no comment could be made on whether the

expression pattern of glandular ER and PR has a role in the etiopathogenesis of the polyp.

There are publications in the literature that mast cells may have a role in polyp formation. Otsuka et al. (22) showed that the number of activated mast cells increased 4-fold in nasal polyps, while Gounaris et al. (23) showed increased mast cell infiltration in intestinal adenomatous polyps and suggested that mast cells play a role in polyp formation. Crow et al. (24) stated that the number of mast cells in the endometrium decreases with advancing age, especially after menopause. Al-Jefout et al. (25) showed that especially tryptase-containing mast cells (MCT) were seen at higher rates in endometrial polyps, and stated that they play a role in polyp formation (26), thanks to tryptase, which is a potent growth factor for epithelial cells. However, as far as we know, there is no study in the literature comparing premenopausal and postmenopausal patient groups in terms of tryptase-containing mast cells, as in our study. In our study, these two patient groups were compared in terms of the number of mast cells per mm^2 in polyps, and no statistically significant difference was found between the two groups in this respect. However, in the postmenopausal patient group, the number of mast cells per mm^2 was higher, unlike the results of Crow et al. Based on this result, it was evaluated that mast cells containing tryptase may have a direct or indirect role in polyp formation, especially in the postmenopausal patient group, similar to the results of Al-Jefout et al. (25).

COXs are enzymes that catalyze the cyclooxygenation and peroxidation steps, which are the first two steps in the synthesis of prostaglandins from arachidonic acid. There are 3 subtypes: COX-1 is an enzyme that is present in many tissues and plays a role in the cytoprotective effect in the gastric mucosa, the integrity of platelet function, and the continuation of renal perfusion, while COX-2 cannot be detected in many tissues and is expressed in activated macrophages and other cells in the inflammation area as a result of inflammatory response-related stimuli. is the "inducible isoform of COX" (27,28). COX-3 is also identified as COX-1b or COX-1v as it is a variant of COX-1. It is particularly sensitive to acetaminophen and its related components and is mostly found in the cerebral cortex and heart (27,29). COX-2 is involved in various stages of carcinogenesis (30,31). COX-2 is important in the regulation of angiogenesis and decidualization in the normal endometrium and in the

regulation of endometrial bleeding (14). It has been shown that COX-2 is overexpressed in endometrial hyperplasia and cancers, and the grade and invasiveness of endometrial cancers are associated with COX-2 expression (14-16).

Maia et al. (32) stated that COX-2 is expressed in the epithelium of postmenopausal endometrial polyps and suggested that COX-2 may have a role in the regulation of polyp development. Erdemoğlu et al. (14) showed COX-2 expression in the endometrial polyps of both premenopausal and postmenopausal patients, and no statistically significant difference was found between the two groups in terms of expression in the epithelium. In our study, similar to these two studies, COX-2 was expressed in endometrial polyps, and there was no difference between epithelial COX-2 expression in polyps of premenopausal and postmenopausal patients. Accordingly, it was evaluated that both groups may have a common pathogenesis in terms of COX-2 in polyp formation.

It is known that MMPs have important effects on the endometrium. It has been shown that the production and activation of MMPs before and during menstruation and the balance of MMP-TIMP affect the bleeding pattern during menstruation (27). MMP-2 and MMP-9 are associated with the destruction of the vessel wall in irregular menstruation (33). Considering the effects of MMPs on the endometrium and the fact that they are affected by estrogen levels, it comes to mind that they may also play a role in the etiopathogenesis of endometrial polyps or may be responsible for abnormal bleeding symptoms in endometrial polyps.

The expression of MMP-2 and MMP-9 in endometrial polyps in premenopausal and postmenopausal patients has not been clearly elucidated. Erdemoğlu et al. also compared MMP-2 and MMP-9 expressions in premenopausal and postmenopausal endometrial polyps, in addition to COX-2 (14). While there was no difference in epithelial MMP-2 expressions between the two groups, it was shown that epithelial MMP-9 expression was significantly higher in the premenopausal group than in the postmenopausal group. In our study, while the expression of MMP-2 and MMP-9 was evaluated, the extent and severity of immunohistochemical staining of the polyp materials of the patients were evaluated separately. There was no statistically significant difference between the two groups in terms of the

prevalence and severity of MMP-9 staining and the prevalence of MMP-2 staining. The intensity of MMP-2 staining was found to be significantly higher in the postmenopausal group than in the premenopausal group, especially in terms of moderate staining. Based on these results, it was evaluated that premenopausal and postmenopausal endometrial polyps may share a common etiopathogenesis, but MMP-2 may have an additional contribution to the formation of postmenopausal polyps.

It is known that COX-2 and MMP-9 are associated with angiogenesis (14) and MMP-2 and MMP-9 play a role in vessel wall deterioration and irregular menstruation (14,33). Considering this information in our study, we investigated whether there is a relationship between the complaints of patients presenting to the outpatient clinic and the expression levels of COX-2, MMP-2, and MMP-9. MMP-2, MMP-9, and COX-2 expressions were compared in the polyps of 18 patients who were completely asymptomatic in the postmenopausal patient group and had an increase in endometrial echo when they applied to the outpatient clinic for routine gynecological examination and 14 patients who presented with the complaint of postmenopausal bleeding. As a result, no statistically significant results were found between the groups ($p>0.05$). However, it was observed that MMP-2 and MMP-9 levels in polyps belonging to patients presenting with postmenopausal bleeding were slightly increased, although not statistically significant, compared to the asymptomatic group. In the study, MMP-2, MMP-9, and COX-2 expressions were also compared in patients who applied to the outpatient clinic with bleeding complaints in the premenopausal period and in patients who applied for non-bleeding reasons. There was no statistically significant difference between the groups. However, as in the postmenopausal patient group, a statistically insignificant but linear relationship was not found. Based on this information, it was evaluated that abnormal bleeding in polyps, especially in postmenopausal patients, may be caused by MMP-2 and MMP-9 expression.

In our study, patients were also compared by dividing them into two groups those with and without breast CA. As a result of the comparison of the groups in terms of ER, PR, and the number of mast cells containing tryptase, COX-2, MMP-2, and MMP-9, no significant difference was found between the groups in terms of these factors. Thus, the aim was to show the distribution in terms of the

markers used in the study in polyps belonging to premenopausal and postmenopausal breast CA patients, and it was determined that the expression of the markers between the groups was homogeneous. Based on these findings, it was thought that breast CA had no effect on the markers included in the study and did not indirectly contribute to the formation of polyps.

Another factor mentioned in the etiology of endometrial polyps is tamoxifen. Tamoxifen is a selective estrogen receptor modulator used in the adjuvant treatment and prophylaxis of ER(+) breast cancers. It provides an antiestrogenic effect on the breast by binding to the estrogen receptor with competitive inhibition (34). Its effect on the uterus is more complex, acting both as an agonist and an antagonist to estrogen. This agonist effect may cause the formation of endometrial polyps, which may be accompanied by simple or complex hyperplasia.

In our study, patients with breast CA were divided into two groups tamoxifen users and non-users, and the role of tamoxifen in polyp formation was investigated. For this purpose, comparisons were made between the groups in terms of ER, PR, and the number of mast cells containing tryptase, COX-2, MMP-2, and MMP-9 in the materials of the patients. As a result of the comparison, no statistically significant difference was found between the groups. Based on these results, it was evaluated that tamoxifen did not play a role in the formation of polyps by any mechanism other than the estrogen agonist effect, and did not affect the development of polyps by changing the expression of the markers investigated in our study.

In the study of Dreisler et al. (5), being overweight and taking HRT in the postmenopausal period were found to be positively associated with the formation of endometrial polyps. In our study, it was not possible to evaluate whether obesity had a role in polyp formation because there was no significant difference between patients in terms of BMI and whether HRT increased the frequency of postmenopausal polyps in the absence of a control group. Postmenopausal patients were divided into two groups those who took HRT and those who did not, and were compared in terms of the factors in our study. The prevalence and severity of MMP-9 staining immunohistochemically in endometrial polyps in the group that received HRT was found to be significantly higher than the group that did not receive it. Based on these results, it was evaluated that HRT might play a role in intermediate steps in polyp formation by increasing

MMP-9 expression. Considering that MMP-9 is one of the MMPs most associated with angiogenesis and has a role in many steps of angiogenesis (35), this additional role in polyp formation was thought to be through angiogenesis. Thus, it was evaluated that a different mechanism may be involved in the formation of postmenopausal polyps compared to premenopausal polyps.

In the study of Dreisler et al. (5), the use of OCT was found to be negatively associated with polyp formation. In our study, premenopausal patients were divided into two groups OCT users and non-users, and compared in terms of the factors used in the study. Since we did not have a control group, it could not be evaluated whether the use of OCT had a direct role in the formation of polyps. In the comparison between the groups, no statistically significant difference was found between the two groups in terms of the markers in our study. Based on these results, it was thought that OCT had no effect on polyp formation or prevention on ER, PR, tryptase-containing mast cells, COX-2, MMP-2, and MMP-9.

In summary, when the data we obtained at the end of our study are evaluated; It was observed that the moderate staining intensity of MMP-2 in the postmenopausal group was significantly higher than that in the premenopausal group, and the number of mast cells was found to be higher in the postmenopausal group, although it was not statistically significant. In addition, it was determined that the prevalence and severity of MMP-9 expression were higher in patients receiving postmenopausal HRT.

Conclusions

The MMP-2, MMP-9, and mast cells may have additional contributions in the stages of endometrial polyp formation in postmenopausal patients. While the role of estrogen in the mechanism of endometrial polyp formation is stated, it is known that it is insufficient to explain the formation of postmenopausal polyps. The possible contribution of MMP-2, MMP-9, and mast cells to the etiopathogenesis may resolve the contradictions in the formation mechanism of postmenopausal polyps. If this information is proven as a result of more comprehensive studies to be done later, it may be possible to prevent endometrial polyps and to create non-surgical treatment options, especially in the general postmenopausal patient group and in patients receiving HRT.

Conflict of interest:

The authors report no conflict of interest.

Funding source:

No funding was required.

Ethical approval:

Ethical approval was obtained from the Haydarpaşa Training Hospital in 09/2010.

Contributions

Research concept and design: **ÖÖ, LT, ZK**

Data analysis and interpretation: **ÖÖ, LT**

Collection and/or assembly of data: **LT, ZK**

Writing the article: **ÖÖ, ZK**

Critical revision of the article: **ÖÖ, LT**

Final approval of the article: **ÖÖ, LT, ZK**

References

1. Reslová T, Tosner J, Resl M, Kugler R, Vávrová I. Endometrial polyps. A clinical study of 245 cases. *Arch Gynecol Obstet.* 1999;262(3-4):133-9.
2. Peterson WP and Novak ER. Endometrial polyps. *Obstet Gynecol.* 1956;8(1):40-9.
3. Moon SH, Lee SE, Jung IK, Jeong JE, Park WY, Yi WH, et al. A giant endometrial polyp with tamoxifen therapy in postmenopausal woman. *Korean J Obstet Gynecol.* 2011;54(12):836-40.
4. Hamani Y, Eldar I, Sela HY, Voss E, Haimov-Kochman R. The clinical significance of small endometrial polyps. *Eur J Obstet Gynecol Reprod Biol.* 2013;170(2):497-500.
5. Dreisler E, Sorensen SS, Lose G. Endometrial polyps and associated factors in Danish women aged 36-74 years. *Am J Obstet Gynecol* 2009;200(2):147.e1-6.
6. Kassab A, Trotter P, Fox R. Risk of cancer in symptomatic postmenopausal women with endometrial polyps at scan. *J Obstet Gynaecol.* 2008;28(5):522-5.
7. Peng X, Li T, Xia E, Xia C, Liu Y, Yu D. A comparison of oestrogen receptor and progesterone receptor expression in endometrial polyps and endometrium of premenopausal women. *J Obstet Gynaecol.* 2009;29(4):340-6.
8. Couse JF, Lindzey J, Grandien K, Gustafsson JA, Korach KS. Tissue distribution and quantitative analysis of estrogen receptor-alpha (ERalpha) and estrogen receptor-beta (ERbeta) messenger ribonucleic acid in the wild-type and ERalpha-knockout mouse. *Endocrinology.* 1997;138(11):4613-21.
9. Couse JF, Korach KS. Estrogen receptor null mice: what have we learned and where will they lead us? *Endocr Rev.* 1999;20(3):358-417.
10. Cohen I, Azaria R, Bernheim J, Shapira J, Beyth Y. Risk factors of endometrial polyps resected from postmenopausal patients with breast carcinoma treated with tamoxifen. *Cancer.* 2001;92(5):1151-5.
11. Cohen I, Perel E, Flex D, Tepper R, Altaras MM, Cordoba M, et al. Endometrial pathology in postmenopausal tamoxifen treatment: comparison between gynaecologically symptomatic and asymptomatic breast cancer patients. *J Clin Pathol.* 1999;52(4):278-82.
12. Cohen I, Bernheim J, Azaria R, Tepper R, Sharony R, Beyth Y. Malignant endometrial polyps in postmenopausal breast cancer tamoxifen-treated patients. *Gynecol Oncol.* 1999;75(1):136-41.
13. Aflatoonian A, Pezeshkpour Z, Mehrrolhasani Y, Tabibnejhad N. The effect of misoprostol on the removal of endometrial polyps: A pilot clinical trial. *Int J Reprod Biomed.* 2022;20(6):461-8.
14. Erdemoglu E, Güney M, Karahan N, Mungan T. Expression of cyclooxygenase-2, matrix metalloproteinase-2 and matrix metalloproteinase-9 in premenopausal and postmenopausal endometrial polyps. *Maturitas.* 2008;59(3):268-74.
15. Li W, Xu RJ, Zhang HH, Jiang LH. Overexpression of cyclooxygenase-2 correlates with tumor angiogenesis in endometrial carcinoma. *Int J Gynecol Cancer.* 2006;16(4):1673-8.
16. Graesslin O, Cortez A, Uzan C, Birembaut P, Quereux C, Darai E. Endometrial tumor invasiveness is related to metalloproteinase 2 and tissue inhibitor of metalloproteinase 2 expressions. *Int J Gynecol Cancer.* 2006;16(5):1911-7.
17. Pal L, Niklaus AL, Kim M, Pollack S, Santoro N. Heterogeneity in endometrial expression of aromatase in polyp-bearing uteri. *Hum Reprod.* 2008;23(1):80-4.
18. Gul A, Ugur M, Iskender C, Zülfikaroglu E, Ozaksit G. Immunohistochemical expression of estrogen and progesterone receptors in endometrial polyps and its relationship to clinical parameters. *Arch Gynecol Obstet* 2010;281(3):479-83.
19. Mittal K, Schwartz L, Goswami S, Demopoulos R. Estrogen and progesterone receptor expression in endometrial polyps. *Int J Gynecol Pathol.* 1996;15(4):345-8.
20. Lopes RG, Baracat EC, de Albuquerque Neto LC, Ramos JF, Yatabe S, Depesr DB, et al. Analysis of estrogen- and progesterone-receptor expression in endometrial polyps. *J Minim Invasive Gynecol.* 2007;14(3):300-3.
21. Sant'Ana de Almeida EC, Nogueira AA, Candido dos Reis FJ, Zambelli Ramalho LN, Zucoloto S. Immunohistochemical expression of estrogen and progesterone receptors in endometrial polyps and adjacent endometrium in postmenopausal women. *Maturitas.* 2004;49:229-33.
22. Otsuka H, Ohkubo K, Seki H, Ohnishi M, Fujikura T. Mast cell quantitation in nasal polyps, sinus mucosa and nasal turbinate mucosa. *J Laryngol Otol.* 1993;107(5):418-22.
23. Gounaris E, Erdman SE, Restaino C, Gurish MF, Friend DS, Gounari F et al. Mast cells are an essential hematopoietic component for polyp development. *Proc Natl Acad Sci U S A.* 2007;104(50):19977-82.
24. Crow J, Wilkins M, Howe S, More L, Helliwell P. Mast cells in the female genital tract. *Int J Gynecol Pathol.* 1991;10(3):230-7.
25. Al-Jefout M, Black K, Schulke L, Berbic M, Luscombe G, Tokushige N, et al. Novel finding of high density of activated mast cells in endometrial polyps. *Fertil Steril.* 2009;92(3):1104-6.
26. Cairns JA, Walls AF. Mast cell tryptase is a mitogen for epithelial cells. Stimulation of IL-8 production and intercellular adhesion molecule-1 expression. *J Immunol.* 1996;156(1):275-83.
27. Clària J. Cyclooxygenase-2 biology. *Curr Pharm Des.* 2003;9(27):2177-90.
28. Morita I. Distinct functions of COX-1 and COX-2. *Prostaglandins Other Lipid Mediat.* 2002;68-69:165-75.
29. Chandrasekharan NV, Dai H, Roos KL, Evanson NK, Tomsik J, Elton TS, et al. COX-3, a cyclooxygenase-1 variant inhibited by acetaminophen and other analgesic/antipyretic drugs: cloning, structure, and expression. *Proc Natl Acad Sci U S A.* 2002;99(21):13926-31.
30. Subbaramaiah K, Dannenberg AJ. Cyclooxygenase 2: a molecular target for cancer prevention and treatment. *Trends Pharmacol Sci.* 2003;24(2):96-102.
31. Funk CD. Prostaglandins and leukotrienes: advances in eicosanoid biology. *Science.* 2001;294(5548):1871-5.

32. Maia H Jr, Maltez A, Studard E, Zausner B, Athayde C, Coutinho E. Effect of the menstrual cycle and oral contraceptives on cyclooxygenase-2 expression in the endometrium. *Gynecol Endocrinol.* 2005;21(1):57-61.
33. Galant C, Berlière M, Dubois D, Verougstraete JC, Charles A, Lemoine P, et al. Focal expression and final activity of matrix metalloproteinases may explain irregular dysfunctional endometrial bleeding. *Am J Pathol.* 2004;165(1):83-94.
34. Gielen SC, Kühne LC, Ewing PC, Blok LJ, Burger CW. Tamoxifen treatment for breast cancer enforces a distinct gene-expression profile on the human endometrium: an exploratory study. *Endocr Relat Cancer.* 2005;12(4):1037-49.
35. Martin MD, Matrisian LM. The other side of MMPs: protective roles in tumor progression. *Cancer Metastasis Rev.* 2007;26(3-4):717-24.