



10.5281/  
zenodo.7689647

# Complications and difficulties due to bonesetter in the treatment of pediatric distal humerus fractures

Mehmet Sait Akar<sup>1</sup> - Sait Anıl Ulus<sup>1</sup> - Fatih Durgut<sup>1</sup> - Sait Dönmez<sup>1</sup>

1. Department of Orthopedics and Traumatology, Medical Faculty of Dicle University, Diyarbakir, Turkey.

## Correspondence

Akar MS, Department of Orthopedics and Traumatology, Medical Faculty of Dicle University, Diyarbakir, Turkey Tel: +90 412 248 8001; Fax: +90 412 248 8523,

## e-mail

[drmsa003@hotmail.com](mailto:drmsa003@hotmail.com)

**Received:** 8 December 2022

**Revised:** 31 December 2022

**Accepted:** 5 January 2023

**Published:** 2 March 2023

## Keywords

- ⇒ Neurovascular injury
- ⇒ Supracondylar humerus fracture
- ⇒ Traditional bonesetter

## ORCID ID of the author(s):

MSA: 0000-0002-2999-2141

SAU: 0000-0003-3270-1648

FD: 0000-0001-5782-4842

SD: 0000-0003-4774-857X

## Abstract

**Objective:** In this study, cases with delayed diagnosis and treatment due to traditional bonesetters were examined and in this article, we aimed to address the problems experienced by patients with supracondylar humerus fractures who were exposed to traditional bonesetters intervention and the physicians who treat these patients.

**Materials and methods:** Thirty-six patients with supracondylar humerus fractures who were admitted to our hospital between January 2017 and December 2020 and were accepted as bonesetters sequelae were retrospectively reviewed. The time between injury and admission to the hospital, skin problems, neurovascular examinations, and soft tissue conditions of the patients were evaluated. The operation time, open or closed reduction, and fixation technique were examined.

**Results:** The mean time between fracture and admission to the hospital was 5.28 days (1-15 days). After the patients were admitted to the hospital, their surgeries were delayed due to edema or skin problems and delayed an average of 15.4 hours (5-48 hours). The mean operative time was 96.3 minutes (38-221 minutes), and 19 patients (52.8%) required open reduction. The mean hospital stay of the patients was 3 days (2-11 days). In the pre-operative evaluation, nerve lesion was detected in 6 patients (16.7%). It is remarkable that the number of patients who applied to our hospital after bonesetters applied in 2020, has increased significantly.

**Conclusions:** The application of bonesetters in children with fractures around the elbow causes a delay in the arrival of patients to the hospital and causes increased complications. The number of applications for bonesetters increased significantly in 2020 due to both the pandemic restrictions and the patients' avoidance of applying to the hospital during the COVID-19 pandemic. Edema and skin lesions as to dislocation sequelae affect the timing of Surgery.

**Cite as:** Akar MS, Ulus SA, Durgut F, Donmez S. Complications and difficulties due to bonesetter in the treatment of pediatric distal humerus fractures. J Clin Trials Exp Investig. 2023;2(1):38-44.

## Introduction

Upper extremity fractures in children constitute 75% of all fractures (1). Supracondylar humerus (SCH) fractures constitute 17.4% of all pediatric fractures, 60% of elbow circumference fractures, and 30% of all extremity fractures in children under 7 years of age (2,3). Most of these fractures (97.7%) are extension type after falling on the open hand, and the remaining 2.2% are flexion type. With these fractures, neurovascular injuries can occur up to 49% and are mostly associated with Gartland type 3 and type 4 fractures (4). Vascular injuries are generally; spasms, intimal damage, and related thrombosis, vessel bending, compression, compression of the vessel between the broken parts, or complete rupture. If not treated appropriately, it can lead to catastrophic complications such as Volkmann ischemic contracture. Inappropriate approaches in the diagnosis and treatment of these fractures cause morbidity and may lead to anxiety and post-traumatic stress in children who are usually at the age of play and school (5). SCH fractures are among the most important topics in orthopedics, as they are encountered very frequently, and cause complications, and the approach to these complications may differ in both diagnosis and treatment.

Traditional bonesetters exist in underdeveloped and developing countries. Bonesetters are people without any medical training. They did not receive training in areas such as bone and ligament anatomy, the bone healing process, and radiographic evaluation. Many have never been to school and are illiterate. Their popularity in society is increasing as a result of the fact that they diagnose fractures in all traumas and spontaneous healing of non-fractured soft tissue injuries within the normal healing process.

Especially in pediatric fractures, children cannot have a say about their own treatment. Families that are not well-educated take their children to bonesetters and prevent them from receiving appropriate treatment (6). In our country (Turkey), all children under the age of 18 are under the guarantee of the state, and all their treatments are covered by the state. Despite this, it is thought-provoking that families still prefer bonesetters. For this reason, although transportation to the doctor and the appropriate hospital seems to be the most important reason for referral to bonesetters, the education level and awareness of the families are also effective. In this study, cases that first applied to bonesetters for a child with supracondylar humerus fracture and who had a delay in reaching the hospital were evaluated. The difficulties and complications encountered were investigated.

## Materials and methods

Thirty-six patients with supracondylar humerus fractures who were admitted to Dicle University Medical School Hospital between January 2017 and December 2020 and were considered to have fracture sequelae were reviewed retrospectively. Patients younger than 18 years of age with isolated supracondylar fractures and admitted to bonesetters before hospitalization were included in the study.

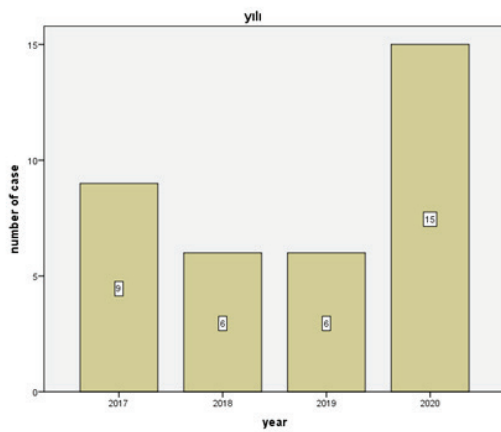
The patients were seen in the emergency department. The materials applied by the bonesetters were removed. The types of materials were recorded. Soft tissue swelling and accompanying skin problems were noted. Detailed neurological examinations of the patients were performed. Ulnar, median, and radial nerve examinations were performed. Damaged nerves were recorded. The radial, ulnar, and brachial artery pulses of the patients were viewed oppositely with the extremity that was intact. Elbow AP-lateral radiographs were obtained on the injured side. Patients with a displaced fracture, where a closed reduction was not possible and surgery was indicated were admitted to the clinic.

The time elapsed between the injury and admission to the hospital was recorded. The time elapsed from the time of hospitalization to the operation of the patients was recorded. The delays of the patients due to swelling or skin problems were determined.

The patients who underwent surgery were taken to the operating table under general anesthesia. Covered under appropriate sterilization conditions. Closed reduction maneuvers were performed on the side to be operated on under fluoroscopy. Open reduction was used in patients who could not achieve adequate reduction after 2 or 3 attempts and in patients with fracture union. For open reduction, lateral or anterior open reduction was applied. Anterior open reduction was performed in patients who were thought to have neurovascular damage. After reduction, fixation was achieved with Martin Kirschner (K) wires. Perioperative fluoroscopy controls were performed. Operative time, open or closed reduction, and fixation technique were recorded for each patient.

Radial, ulnar, and median nerve examinations were performed for postoperative neurovascular evaluation. Radial, ulnar, and brachial artery examinations were performed. X-ray controls were performed in the early postoperative period and at the 1st, 3rd, 6th, and 12th months.

The study was approved by the local ethics committee (07.01.2021/44).



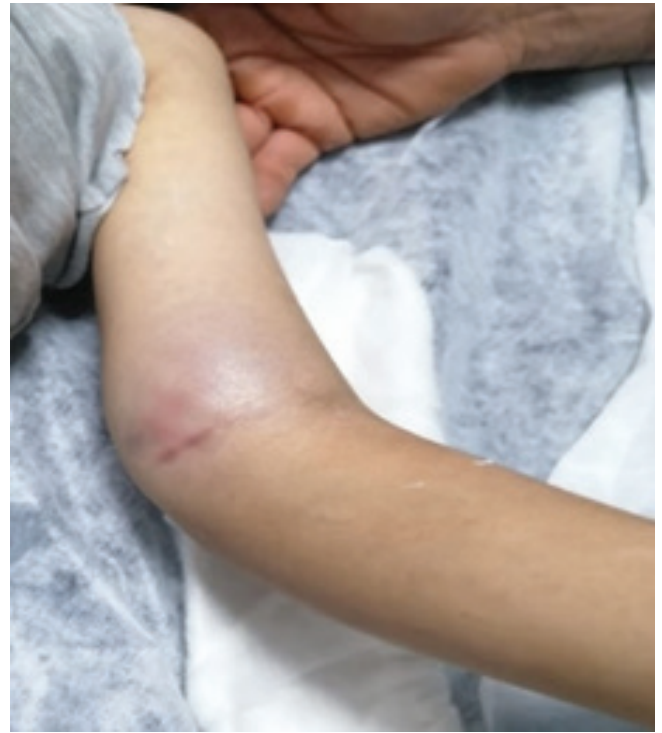**Figure 1:** Number of cases by year

### Statistical analysis

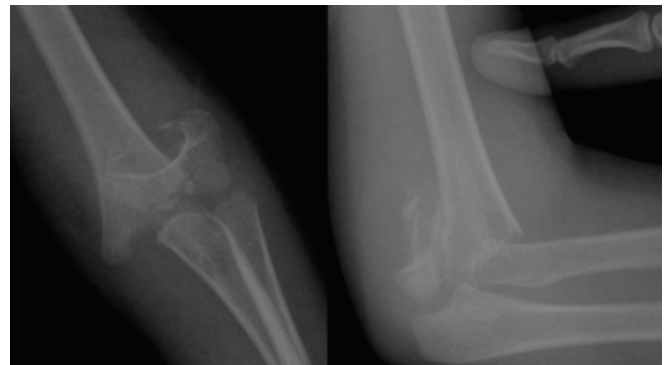
Statistical analysis for patients' data, involving descriptive statistics, frequency, and other characteristics was performed for all items. Continuous data were expressed as mean  $\pm$  standard deviation. To determine whether the data had a normal distribution, the continuous variables were analyzed with Shapiro–Wilk test. Continuous, and normally distributed variables were compared using Student's T-test. Non-parametric tests were chosen when the data did not fit the normal distribution. The categorical variables were evaluated by the chi-square test and some data by Fisher exact test, as needed. Analyses were performed using SPSS Statistics for Windows, Version 26.0 (IBM Corp., Armonk, NY, USA). All p-values were two-sided and  $p \leq 0.05$  was considered statistically significant.

### Results

Twenty-six (72.2%) of the patients were male and 10 (27.8%) were female. The mean age was 4.7 years (2-10). While 3 of the patients had fractures after high-energy injury, 33 patients had a low-energy injury mechanism. The mean follow-up period was 22.1 months (12-38). The mean delay time between fracture formation and admission to the hospital was 5.28 days (1-15). After the patients were admitted to the hospital, their surgeries were delayed due to edema or skin problems and an average of 15.4 hours (5-48) passed. The mean operative time was 96.3 minutes (38-221), and 19 patients (52.8%) required open reduction. The mean hospital stay of the patients was 3 days (2-11). Casting was provided in one patient, and fixation was achieved with 2-3 K-wires in 35 patients. In the preoperative evaluation, nerve lesion was detected in 6 patients (16.7%). Of these patients, 4 patients had median, 1 patient had ulnar and 1 patient had radial nerve palsy. In one patient who developed postoperative ulnar nerve palsy, the medial wires



**Figure 2A:** Images of the case in the emergency room



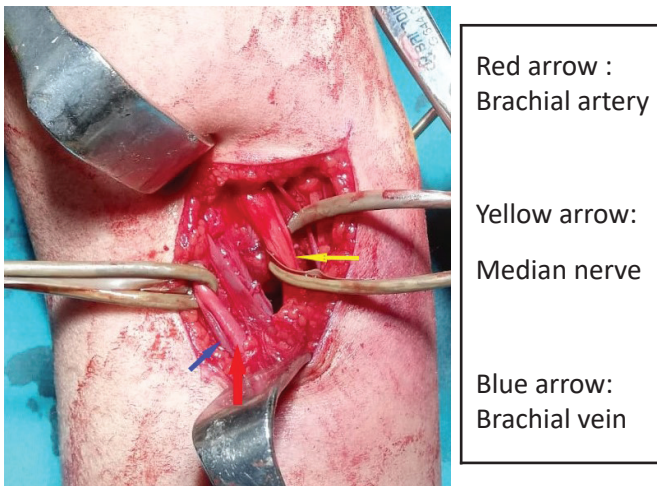
**Figure 2B:** Preoperative radiographs of the case

were removed. In the follow-ups, complete recovery was detected in patients with nerve damage, except for one patient whose anterior interosseous nerve damage continued.

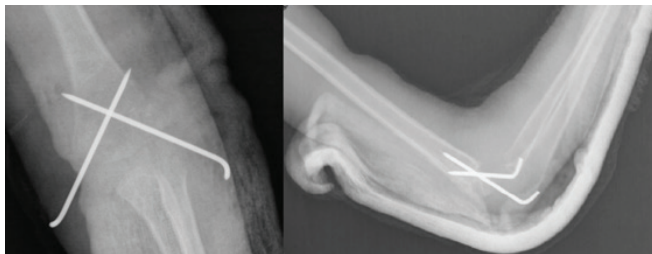When the distribution of cases by year was examined, it was found that 15 (41.7%) cases applied in 2020. Case numbers are given in (**Figure 1**).

Arterial exploration was performed because no flow was detected by Doppler in 2 of 11 (31.6%) patients with pulseless hands. The brachial artery was repaired after embolectomy with Fogarty no. 3 by the cardiovascular surgeon team. Exploration was not performed due to the presence of Doppler flow in 9 of the patients. Images of the patient with brachial artery repair are given in (**Figure 2a, 2b, 2c, 2d**).

The number of patients who developed swelling or



**Figure 2C:** Intraoperative view of the case



**Figure 2D:** Postoperative radiographs of the case.

bullae on the skin was 15 (41.7%). These pathologies were observed more frequently in patients who were stabilized using different materials, especially in full extension. While the meantime to hospital admission after fracture was 7.1 days in the patient groups with and without skin lesions, a delay of 3.9 days was found in the group without skin lesions (**Table 1**). A significant difference was found between the groups ( $P=0.012$ ). **Figure 3** shows a patient with a pulseless hand who presented late as a result of bonesetter intervention and had swelling, ecchymosis, and skin lesions.

Honey, animal fats, soap, eggs, cotton fabric, cardboard, tight bandaging, and wood chips are used by bonesetters for fixation. We found that a full-extension medical cast was used in one patient. Recently, bonesetters using medical plasters have been encountered. All other methods used partially flexible materials.

**Discussion**

Musculoskeletal traumas are quite common in society. People exposed to these traumas generally recover without sequelae, although they occasionally develop disabilities. Treatment of fractures and dislocations due to pathological or traumatic causes has been practiced since ancient times and includes various

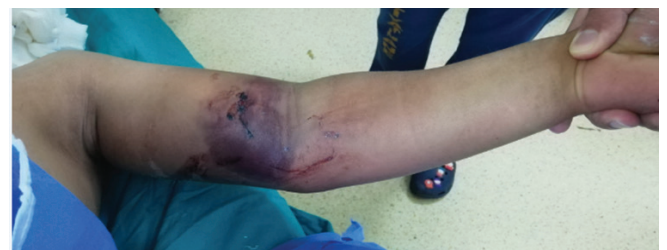**Table 1:** General findings

	N	%
Male	26	72.2
Female	10	27.8
Mean age (years)	4.7	2-10
High injury	3	8.3
Low injury	33	91.7
Hospital admission after fracture (day)*	7,1	
Delay time (day)*	5,28	1-15
Mean operative time (minutes)*	96,3	38-221
Bullae or swelling	15	41.7
Pulseless hands	11	30.5
No arterial flow	2	5.5
Nerve lesions	6	16.7
<i>Ulna</i>	1	2.7
<i>Radial</i>	1	2.7
<i>Median</i>	4	11.1
Hospital stay (days)*	3	2-11
Follow-up (days)*	22,1	12-38

\*Mean (range)

techniques (1,5). Orthopedic devices, and diagnostic and treatment techniques have undergone significant changes and advances over the past few centuries as a result of changes and developments in the medical and surgical professions. Modern medical diagnosis and treatment techniques are used in the treatment of fractures and dislocations (5,6). Despite this, bonesetter treatments continue to play an important role in the treatment of fractures and dislocations in our country as well as in many developing countries and continues to be an important problem.

To treat fractures and dislocations, bonesetters have developed interesting methods over time. These methods can sometimes be dangerous. While patients treated by bonesetters sometimes recover,



**Figure 3:** Patient who applied to us after applying to a bonesetter

a significant number of them have to continue to live with permanent sequelae. The fact that children make up the majority of patients and their ability to remodel is strong can compensate for some sequelae. As a matter of fact, sometimes good results can be obtained with bonesetter intervention for fractures that occur in the diaphysis and metaphyseal regions of bones such as the humerus, radius, ulna, and tibia (7). However, these results depend on the remodeling capacity, and these good results cause the public to trust bonesetters. Bonesetter intervention for open fractures and periarticular fractures leads to poor results. Undesirable complications such as nonunion, malunion, osteomyelitis, septic arthritis, and gangrene can be seen. In the developing countries of Africa, gangrene resulting from poor treatment of bonesetters is the primary cause of lower extremity amputations (8).

Adding a bonesetter intervention to a fracture that is open to complications such as SCH fractures has led to an increase in the number of complications. Considering that all physicians in the world work in centers with different trauma levels, accepted approaches to these complications can be considered valuable. Neurovascular injuries are common after SCH fractures (8,9). The most accepted approach in such a fracture is that the fracture should be reduced as soon as possible. After the reduction, the path to be followed should be chosen according to the circulation of the hand.

If circulation is good and pulses are palpable, routine follow-up is performed. If circulation is poor and pulses are not palpable, explore for vessel damage. If circulation is good and pulses are not palpable, treatment is controversial. In this case, there are those who advocate waiting and following closely, and there are those who advocate immediate surgery for vascular damage.

In the study of Ozkul et al. (9), the vascular repair was performed in 3 patients with the circulatory disorder after a reduction, out of 42 patients with pulseless hands due to SCH fractures. In 2 patients with no pulse but no flow with Doppler but good circulation, the flow was taken one day later, the flow was obtained with Doppler in 10 patients, and pulse was obtained after reduction in 27 patients.

Pulseless hands can be seen in 2-20% of children after SCH fractures (10). The overall incidence of vascular damage varies between 3-15% (11). In our patients, this rate was 31.6%. We think that this high rate is due to delay, incorrect reduction, and bandaging techniques.

Nerve damage may be due to overstretching,

compression, direct damage to the fractured fragment, or iatrogenic. The median nerve is most commonly injured in extension-type fractures, the ulnar nerve is most commonly injured in flexion-type fractures and iatrogenic. These injuries are in the form of neuropraxia between 86-100% and heal spontaneously between 2-6 months (12). Garbuz et al. (13) reported that neurologic injury accompanies the pulseless hand at a rate of 60%. A meta-analysis of more than 5000 fractures reported an overall rate of traumatic neuropraxia of 11.3%, with neuropraxia-related extension fractures most commonly involving the anterior interosseous nerve (34.1%) and flexion injuries-related neuropraxias most commonly involving the ulnar nerve (91.3%). (14). In our patient group, the nerve damage was seen in 16.7%. Although some of the nerve injuries are traumatic, we think that some of them may be due to inappropriate reduction attempts, good management of fracture swelling, and fixation materials that apply pressure to the wrong place.

In a study examining open reduction rates after SCH fractures, open reduction was performed in 44 of 1329 patients with type 3 and type 4 fractures, and the open reduction rate was found to be 3.3% (15). In a study in which US national databases were examined, 29,642 patients were evaluated and the open reduction rate was found to be 12.7% (16). In our study, 52.8% of patients required open reduction (19 of 36 patients). The swelling and formation of callus tissues due to the late admission of the patients made closed reduction difficult and increased the number of open reductions.

In the pediatric population, SCH fractures are usually treated in an emergency fashion. Non-surgical treatment of these fractures has been replaced by surgical stabilization in the last few decades. Historically, the rationale for this type of emergency care has been to reduce swelling to reduce the risk of perioperative complications such as compartment syndrome, infection, and nerve damage, as well as to reduce the likelihood of needing open reduction. In a study examining 190 types 3 SCH fractures, it was shown that the probability of conversion to open surgery increases 4-fold every 5 hours starting 15 hours after injury, and open reduction is required after 32 hours (17).

In a study examining 396 type 3 SCH fractures, 243 patients (61.4%) in the early treatment group and 153 patients (38.6) in the late treatment group were analyzed, and closed reduction failure and transition to open reduction were found to be significantly higher in the delayed treatment group than in the early treatment group. (18). In another study, it was

found that the need for open reduction was higher in patients who were operated after 8 hours compared to those operated before 8 hours (19). There are also studies in the literature reporting that open reduction and complication rates are not associated with the time until surgery, but when these studies are examined, it is seen that patients are divided into two groups according to 8 or 12 hours (20,21). The mean time of admission to the hospital for our patients was 5.28 days, the time from admission to surgery was 15.4 hours, and the mean operative time was 96.3 minutes. The mean duration of surgery was also found to be higher than in the literature (21,22,23).

## Conclusions

In developing countries with low levels of education, bonesetter sequelae are a serious problem. Sequelae remain in the majority of joint fractures, especially elbow fractures. Bonesetter interventions, which often apply treatment that a doctor would not recommend and cause complications and complicate treatment, are still preferred. It will be beneficial to inform the society on this issue and to carry out public health education programs.

**Conflict of interest:** The authors report no conflict of interest.

**Funding source:** No funding was required.

**Ethical approval:** The study was approved by the local ethics committee (07.01.2021/44).

**Acknowledgement:** No

**Peer-review:** Externally. Evaluated by independent reviewers working in at least two different institutions appointed by the field editor.

## Contributions

Research concept and design: MSA, SAU, FT

Data analysis and interpretation: MSA, SD

Collection and/or assembly of data: MSA, SAU

Writing the article: MSA, SAU

Critical revision of the article: MSA, SAU, FT

Final approval of the article: MSA, SAU, FT, SD

All authors read and approved the final version of the manuscript.

## References

- Klimkiewicz JJ, Bradley JP, Sawyer JR. Pediatric elbow fractures and dislocations. In: DeLee D, editor. Orthopaedic sports medicine. Principles and practice. 2nd ed., Vol. 1. Philadelphia: Saunders; 2003.
- Cheng JC, Ng BK, Ying SY, Lam PK. A 10-year study of the changes in the pattern and treatment of 6,493 fractures. *J Pediatr Orthop.* 1999;19(3):344–50.
- Landin LA, Danielsson LG. Elbow fractures in children. An epidemiological analysis of 589 cases. *Acta Orthop Scand.* 1986;57(4):309-12.
- Ramachandran M, Birch R, Eastwood DM. Clinical outcome of nerve injuries associated with supracondylar fractures of the humerus in children: the experience of a specialist referral center. *J Bone Joint Surg Br.* 2006;88(1):90-4.
- Kara A. A review of childhood anxiety. *J Clin Trials Exp Investig.* 2022;1(3):64-70.
- Omololu B, Ogunlade SO, Alonge TO. The complications seen from the treatment by traditional bonesetters. *West Afr J Med.* 2002;21(4):335-7.
- Alemdar C, Azboy İ, Demirtaş A ve ark. Bölgemizdeki kırıkçı sekellerinin ortopedik açıdan değerlendirilmesi. *İstanbul Med J.* 2014;15:122-6.
- Gözen A, Doğan A, Gökalp MA, Ünsal SŞ, Güner S. 2008-2012 yılları arasında sınıklı müdahalesi sonrasında kliniğimize başvuran hastaların analizi. *Tıp Araştırmaları Dergisi.* 2015;13(1):15-9.
- Özkul E, Gem M, Alemdar C, Arslan H, Azboy İ, Çelik V. Çocuklarda suprakondiller humerus kırığı sonrası damarsal yaralanmalar. *Ulus Travma Acil Cerrahi Derg.* 2016;22(1): 84-9.
- Cambon-Binder A, Jehanno P, Tribout L, Valenti P, Simon AL, Ilharreborde B, et al. Pulseless supracondylar humeral fractures in children: vascular complications in a ten year series. *Int Orthop.* 2018;42(4):891-9.
- Leiblein M, Lustenberger T, Schulz AK, Schmitz-Rixen T, Marzi I. Neurovascular complications after supracondylar humerus fractures in children. *Trauma Case Rep.* 2017;8:16–9.
- Babal JC, Mehlman CT, Klein G. Nerve injuries associated with pediatric supracondylar humeral fractures: a meta-analysis. *J Pediatr Orthop.* 2010;30(3):253-63.
- Garbuz DS, Leitch K, Wright JG. Treatment of supracondylar fractures with an absent radial pulse. *J Paediatr Orthop.* 1997;17(3):303-10.
- Duffy S, Flannery O, Gelfer Y, Monsel F. Overview of the contemporary management of supracondylar humeral fractures in children. *Eur J Orthop Surg Traumatol.* 2021;31:871–81.
- DeFrancesco CJ, Shah AS, Brusalis CM, Flynn K, Leddy K, Flynn JM. Rate of Open Reduction for Supracondylar Humerus Fractures Varies Across Pediatric Orthopaedic Surgeons: A Single-Institution Analysis. *J Orthop Trauma.* 2018;32(10):400-7.
- Holt JB, Glass NA, Bedard NA, Weinstein SL, Shah AS. Emerging U.S. National Trends in the Treatment of Pediatric Supracondylar Humeral Fractures. *J Bone Joint Surg Am.* 2017;99(8):681-7.
- Yildirim AO, Unal VS, Oken OF, Gulcek M, Ozsular M, Ucaner A. Timing of surgical treatment for type III supracondylar humerus fractures in pediatric patients. *J Child Orthop.* 2009;3(4):265-9.
- Loizou CL, Simillis C, Hutchinson JR. A systematic review of early versus delayed treatment for type III supracondylar humeral fractures in children. *Injury.*

2009;40(3):245–8.

19. Walmsley PJ, Kelly MB, Robb JE, Annan IH, Porter DE. Delay increases the need for open reduction of type-III supracondylar fractures of the humerus. *J Bone Joint Surg (Br)*. 2006;88(4):528–30.
20. Abbott MD, Buchler L, Loder RT, Caltoun CB. Gartland type III supracondylar humerus fractures: outcome and complications as related to operative timing and pin configuration. *J Child Orthop*. 2014;8(6):473-7.
21. Sibinski M, Sharma H, Bennet GC. Early versus delayed treatment of extension type-3 supracondylar fractures of the humerus in children. *J Bone Joint Surg (Br)*. 2006;88(3):380–1
22. Striano BM, Brusalis CM, Flynn JM, Talwar D, Shah AS. Operative Time and Cost Vary by Surgeon: An Analysis of Supracondylar Humerus Fractures in Children. *Orthopedics*. 2019;42(3):e317-e321.
23. Shon HC, Kim JW, Shin HK, Eugene K, Park SJ, Park JK et al. Does the timing of surgery affect outcomes of gartland type III supracondylar fractures in children? *Pediatr. Traumatol. Orthop. Reconstr. Surg*. 2019;7:25–32.

**Publisher's Note:** Unico's Medicine remains neutral with regard to jurisdictional claims in published maps and institutional affiliation